

Scorpion stings in Buenos Aires, Argentina: Epidemiological and clinical aspects Picaduras de escorpión en Buenos Aires, Argentina: aspectos clínicos y epidemiológicos

Fernández, Marisa L.; Lloveras, Susana C.; Falcone, Claudia; González, Gustavo; Garro, Santiago; Echazarreta, Sofía; Martino, Olindo†; Orduna, Tomas A.

Centro Municipal de Patología Regional Argentina y Medicina Tropical (CEMPRA-MT), Hospital de Infecciosas F.J. Muñiz, Uspallata 2272, (C1282ADE) Ciudad Autónoma de Buenos Aires. †in memoriam

cempramt@intramed.net

Recibido: 3 de febrero de 2018

Aceptado: 1 de mayo de 2018

Abstract. In Argentina scorpion stings are the leading cause of venom-related injury to human. Since the beginning of the 20th century *Tityus trivittatus* is found in Buenos Aires. Scorpion envenomation is a neurotoxic syndrome with local symptoms and systemic manifestations. It could develop cardiac failure, acute pulmonary edema, shock and death. Fortunately, most of the scorpion stings in adult people in Buenos Aires are mild envenomations. A retrospective, descriptive and cross sectional study based on data collected from medical records of patients followed between 1982 and 2013 were done. We compiled a total of 141 human scorpion stings and 115 arthropod captures: 88 *T. trivittatus*, 10 *Bothriurus bonariensis* and 17 missed data. The accidents occurred more frequently in the eastern and oldest neighborhoods of the city. Eighteen patients had mild systemic manifestation. There was not any death. Twelve patients received scorpion antivenom. Although recently there was a severe case in 5 years old boy and in some provinces in Argentina death have been reported, most of the envenomations are mild. We observed inadequate treatment in some patients; it is important training on the correct management and prevention of this envenomation.

Keywords: Scorpion stings; Buenos Aires; *Tityus trivittatus*; *Bothriurus bonariensis*.

Resumen. En Argentina el escorpionismo es el principal envenenamiento por animales ponzoñosos. Desde comienzos del siglo XX, *Tityus trivittatus* ha sido descrito en Buenos Aires. El escorpionismo es una intoxicación que produce un síndrome neurotóxico con síntomas locales y manifestaciones sistémicas. Puede desencadenar insuficiencia cardiaca, edema agudo de pulmón, shock y muerte. Afortunadamente, la mayoría de los accidentes con escorpiones en adultos en Buenos Aires son intoxicaciones leves. Se realizó un estudio retrospectivo, descriptivo y transversal basado en información recolectada de las historias clínicas desde 1982 hasta 2013. Se recolectó información sobre un total de 141 intoxicaciones por escorpiones y 115 capturas de artrópodos: 88 *T. trivittatus*, 10 *Bothriurus bonariensis* y 17 sin identificar. Los accidentes sucedieron más frecuentemente en los barrios del este y más antiguos de la ciudad. Dieciocho pacientes tuvieron síntomas sistémicos leves. No hubo ninguna muerte. Doce pacientes recibieron antiveneno. La mayoría de los envenenamientos fueron leves, aunque recientemente se produjo un caso grave en un niño de 5 años y en algunas provincias se han registrado muertes. Hemos observado un tratamiento inadecuado en algunos pacientes por lo que consideramos que sería importante capacitar en el correcto manejo y prevención de este envenenamiento.

Palabras claves: Escorpionismo; Buenos Aires; *Tityus trivittatus*; *Bothriurus bonariensis*.

Introduction

Scorpion envenomation is a major public health problem in certain parts of the world, such as North Africa and North and South America (Chippaux and Goyffon 2008; Khattabi *et al.* 2011). Although the mortality is low there is substantial morbidity and, among children, a risk of death (Isbister and Bawaskar 2014). In Argentina, scorpion stings are the leading cause of venom-related injury to the human in the last decades (Ministerio de Salud de la Nación 2011). It is an emergent public health

problem on the most important cities in the center and north of the country.

There are many different species of scorpions in the country. Some of them, such those belonging to Bothriuridae family, do not have medical importance in humans. On the other hand, members from Buthidae family, like those scorpions that constitute the *Tityus* genus, can be responsible for severe envenomation.

The species *B. bonariensis*, from Bothriuridae family, are commonly found in the sub-

urban belt around the City of Buenos Aires. The *Tityus* genus is represented by 8 species in Argentina: *T. trivittatus*, *T. confluens*, *T. argentinus*, *T. uruguayensis*, *T. bahiensis*, *T. serrulatus*, *T. paraguayensis* and *T. curupi* (Martino *et al.* 2001; de Roodt *et al.* 2003, 2014; Ojanguren-Affilastro *et al.* 2017). While *T. serrulatus* has been described in two north-east provinces (Camargo and Ricciardi 2000), along with the border with Brazil (Bortoluzzi *et al.* 2007), it would not be considered as a local established species yet.

Tityus trivittatus, *T. serrulatus*, *T. bahiensis* and *T. confluens* sting can be life-threatening, especially in children and elderly people with comorbidities. *T. trivittatus* is found in Buenos Aires since beginnings of the 20th century. Fortunately, most of the scorpion stings in adult people in Buenos Aires are mild envenomations. Until nowadays, it has been communicated only two severe scorpion envenomation in a 4 years-old girl in 2009 (Docampo and Fernandez 2011; Blanco *et al.* 2012) and at the beginning of 2017, in a 5 years-old boy (ATA 2018).

Scorpion envenomation is a neurotoxic syndrome with local and systemic symptoms. Usually, local pain appears immediately, it is intense and stinging, and irradiates to close anatomic areas. Discrete edema could be observed at the sting site, and occasionally is possible to localize the point of inoculation. Other local symptoms are paresthesia, piloerection, and chills without tissue damage. Systemic manifestations are due to neuronal excitation which results in autonomic stimulation (sympathetic and parasympathetic). They could develop cardiovascular, respiratory and/or neurological disorders with or without some general manifestations such as glandular hypersecretion, abdominal pain, muscles cramps and vomiting. Unusually, they could progress to cardiac failure, acute pulmonary edema, shock, and death, which up to date, were not observed in Buenos Aires city.

In Argentina, for therapeutic guidance and prognostic, envenomation is classified as mild, moderate and severe according to the intensity of the symptoms.

Mild: presence of local manifestations only.

Moderate: low-intensity systemic manifestations may occur, such as diaphoresis, nausea, few vomiting episodes, without cardiovascular or respiratory involvement.

Severe: systemic symptoms as alternating

agitation and prostration, vomiting episodes, excessive salivation, profuse diaphoresis, hypothermia, tachydyspnea, bronchorrhea, tachy or bradyarrhythmias, arterial hyper or hypotension and, rarely, muscle spasms and seizures.

According to Argentinean scorpion stings guidelines, moderate and severe scorpion envenomation require hospitalization in a critical care unit and early antivenom administration, while mild severity intoxication needs 6 hours observation (Boyer *et al.* 2009; Ministerio de Salud de la Nación 2011; Blanco *et al.* 2012; de Roodt 2014).

The aims of this study were to describe clinical, epidemiological data and species of scorpions captured linked to the envenomation cases assisted at the Tropical Medicine Unit between 1982 and 2013.

Method

This manuscript is a single-center retrospective, descriptive and cross-sectional study based on data collected from patient's medical records at the Tropical Medicine Unit between January 1982 and December 2013.

The final studied population consisted of 145 medical records, which were analyzed and reviewed using a specific research form. The variables collected from the patients were gender, age, time of sting, location of sting, clinical symptoms and treatment, and features from the accident like identification of the scorpion species, place and date of the accident.

Results

We compiled a total of 141 human scorpion stings and four scorpion captures without stings, between 1982 and 2013.

The gender distribution of the victims was: 54% males and 46% females. The average age of the patients was 37 years old (range 1.5 - 81 years old). Scorpion stings have been mostly seen in patients between 21 - 50 years old, this group consists 71% of the population in this series. The gender distribution of the patients by age is displayed on *Figure 1*.

In the last decade, the number of notifications of scorpion envenomation has slightly increased in our series, in concordance with the observations at national level as it shows in the *Figure 2*. Seventy-one percent of the scorpion stings occurred in Buenos Aires City, 26% in the suburban belt around Buenos Aires, and 3% in other provinces. There was a total of 115

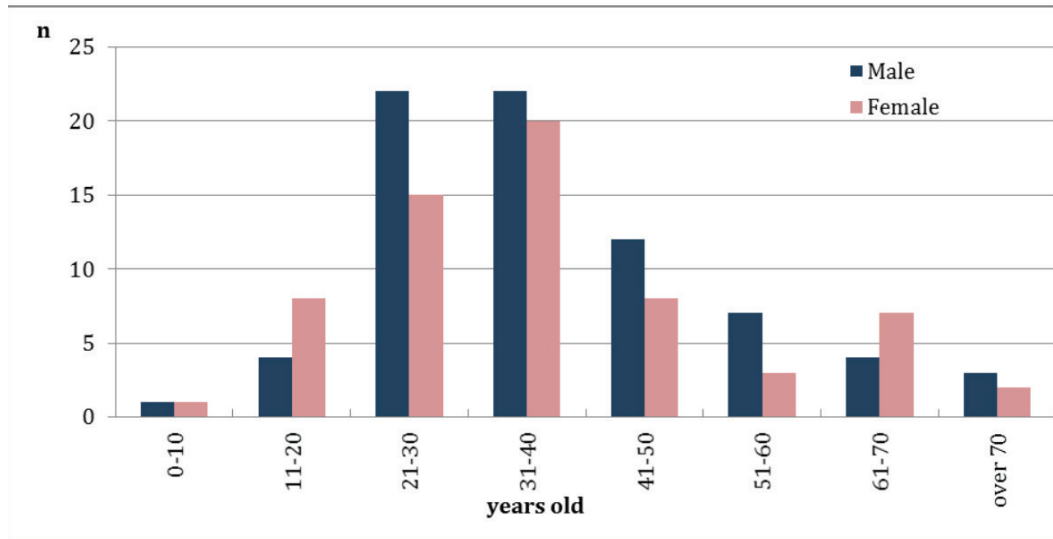


Figure 1. Gender distribution of patients by age range.

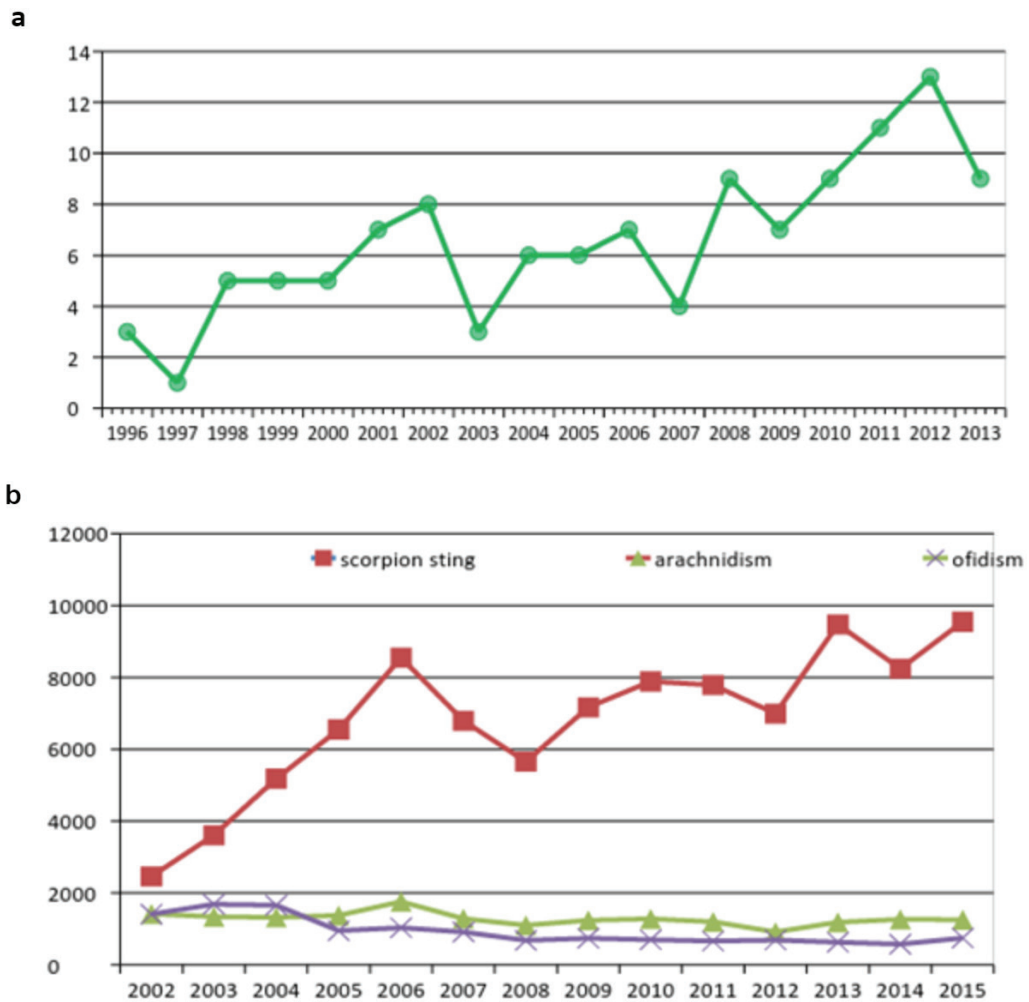


Figure 2. a) Distribution of scorpion sting notifications per year in the Tropical Medicine Unit between 1996 and 2013. b) National distribution of scorpion stings, arachnidism and ofidism per year between 2002 and 2015 (SNVS- Sistema Nacional de Vigilancia de la Salud).

scorpion captures: 88 *T. trivittatus*, 10 *B. bonariensis* and 17 missed data. In Buenos Aires City, 99% were *T. trivittatus* and 1% *B. bonariensis*. In the suburban belt, 48% were *T. trivittatus*, 35% were *B. bonaerensis* and the rest were missed data.

The accidents occurred more frequently in the eastern and oldest neighborhoods of the city and were related to trains and metro railways as it is shown in Figure 3, as described by Blanco *et al.* (2015).

Most of the accidents (85%) occur between October and March (spring and summer season) (Figure 4).

Sixty-eight percent of the scorpions were found inside the home (40% in rooms, 18% in kitchens, 10% in bathrooms, 11% in basements, and the rest did not specify the area), 13% peri-domiciliary and 19% on the streets, pavements and squares.

The anatomical site of envenomation was available in 138 patients. The most common sites of stings were in limbs, 47% in upper limbs and 42% in lower limbs. The stings in feet were mainly due to an accidental encounter with the scorpion while putting on shoes. The accidents in hands, more frequently in women (24 women and 11 men), were due to domestic activity such as cleaning, especially while squeezing cloth, tiding and gardening. The trunk stings occurred mostly while sleeping or resting. Some uncommon stings localized in head and neck happened while sleeping.

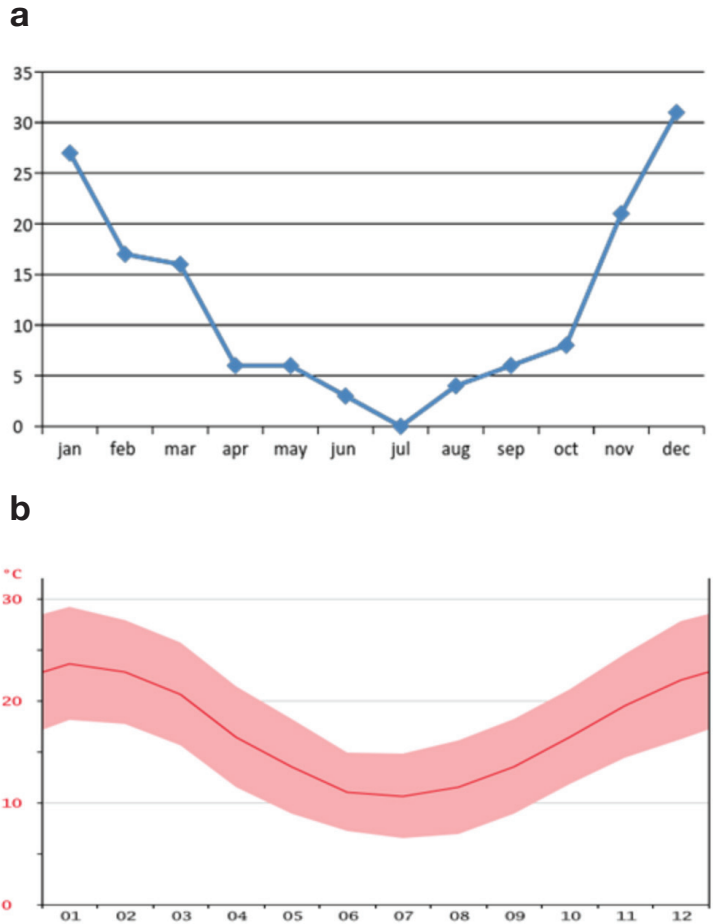


Figure 4. a) Distribution of scorpion stings along the year. b) Buenos Aires City climate graph showing average temperature along the year (<http://es.climate-data.org/location/1207/>)

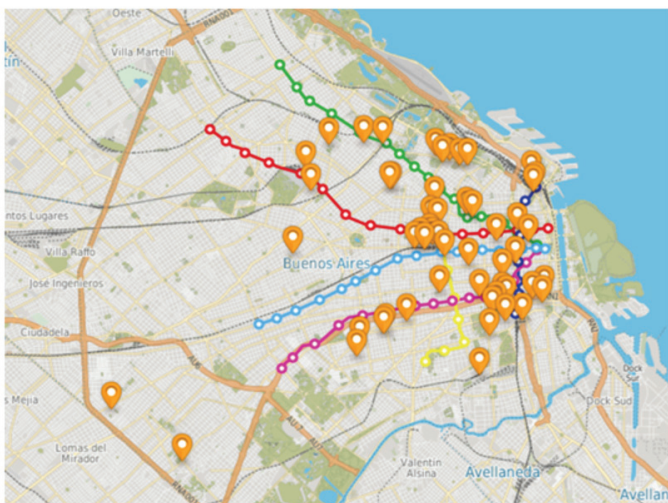


Figure 3. Scorpion location in Buenos Aires city (<https://mapa.buenosaires.gob.ar>). The subways lines are represented by green, red, light blue, pink, yellow and blue lines and the train rails by gray dotted lines.

All patients referred local symptoms, 94% had intensive pain, 55% had inflammatory signs (erythema and mild edema) and 21% had local paresthesias.

Only 18 patients had mild systemic manifestations: arterial hypertension or hypotension, tachycardia, myalgia, and sialorrhea. No death events were registered.

Twelve patients were treated with scorpion antivenom and 23 patients received glucocorticoid therapy, five patients received prophylactic antibiotic therapy, as well as NSAID (non-steroidal anti-inflammatory drugs) and antihistamine therapy at the emergency unit.

Discussion

This study reports a single-center retrospective analysis of scorpion stings in patients assisted in the Tropical Medicine Unit, in the Metropolitan Area of Buenos Aires ("AMBA")

from Spanish). Most patients were male and adults and that could explain the lack of severe envenomation cases, more frequent in children. It has been reported that *T. trivittatus* stings killed 30 children in provinces of the Center and North of Argentina between 2001 and 2012 (Martino *et al.* 2001; Piola *et al.* 2006; de Roodt 2009; de Roodt 2014). Two more cases occurred in 2012 and 2016 in Catamarca province, two young patients of 15 and 17 years old had severe scorpion sting envenomation, and one of them died (El Ancasti 2012; El Ancasti 2016).

In this study, *T. trivittatus* was the prevalent scorpion with high-density distribution in the old neighborhoods of the city, as has been already reported (Salomón and de Roodt 2000; de Roodt *et al.* 2003; 2014; Blanco *et al.* 2016). As they described, it is possible to visualize spreading route along the subway and train rails from the east old neighborhoods to the west side of the city.

Since 2003, *T. confluens* was recognized as responsible for deaths in Argentina with some fatal cases involving children in the Northwestern provinces of Tucuman, Catamarca and Jujuy (de Roodt 2009). *T. serrulatus*, another species of medical importance, has been occasionally captured on the Northeast of Argentina. *T. confluens* and *T. serrulatus* have not been identified in AMBA yet.

It has been observed a slight increase of scorpion envenomation reports in the last years, the same phenomenon happens at national level, while arachnoidism and ofidism reports remain stable (Figure 2 a, and b). This could be due to an increase of scorpions' activity and other environmental phenomena, such as the facultative parthenogenetic characteristic of *T. trivittatus* and the scarce of natural predators in a big city like Buenos Aires (de Roodt 2014).

Scorpions were found mostly inside the houses, in relation with warm and humid places, such as rooms, kitchens, and toilets. Specimens were found in different levels from underground up to the 9th floor, as well it was previously described (de Roodt 2014; Blanco *et al.* 2016).

In concordance with other reports, this study support there the density of *T. trivittatus* for Buenos Aires City (99% of the scorpion captures) is greater than for the surrounded belt of Buenos Aires, where coexists with *B. bonariensis* (Salomon and de Roodt 2001).

The specific antivenom anti-*Tityus trivittatus* is

produced by the National Institute for Production of Biologics, ANLIS "Dr. C. Malbrán" of the Ministry of Health of Argentina, through the immunization of horses with *Tityus trivittatus*' venom. It is freely distributed all over the country by the Ministry of Health (de Roodt 2014).

Twelve patients with mild systemic symptoms received specific antivenom. In these cases patient's anxiety and fear were mistaken as systemic symptoms, probably due to physician's little knowledge on scorpion envenomation. Mild poisoning does not require antivenom administration, it can be managed with NSAID or local lidocaine administration for pain therapy, and to calm patient's fears. In addition, some patients received inappropriate treatment (useless for scorpion sting), like glucocorticoids and antibiotic prophylaxis.

Another important issue about scorpion stings is prevention. People should receive indications to shake out shoes, clothes, and canvas; to dislodge any scorpions and to remove all trash, logs, boards, stones, bricks and other objects around the house. It should also be indicated to wear shoes and gloves when working outdoors. Place mesh underneath the grate of the drain. Also, it is possible to conduct an active search, and capture or kill the scorpions. The use of chemicals or the introduction of natural predators (cats, chickens) are other options available, although the use of chemicals is not recommended unless an order and cleaning of the environment has been previously conducted. (Ministerio de Salud de la Nación 2011; de Roodt 2014; mayoclinic.org 2016; msal.gov.ar 2018).

Conclusions

We reported the epidemiological and clinical characteristics of scorpion poisoning attended in a single center in AMBA. This envenomation could be life threatening, nevertheless, it is treatable and preventable. In general, the findings regarding scorpion accidents are consistent with others reports. The stings occur mostly in Buenos Aires city and the most common species found was *T. trivittatus*. Most of the envenomations were mild, in contrast with the severity described in some provinces in Argentina, where death have been reported. Even the antivenom produced in our country is enough to cover the treatment demands, this series shows it could be some overuse. It is important a responsible use since the antivenom is a scarce resource difficult to obtain.

This is a retrospective study, we considered that a prospective one is needed, to focus on potential complications of scorpion envenomation and identifying early markers of severity, such as electrocardiogram changes, echocardiographic changes, serum markers of cardiac distress and others.

It is important to continue with the epidemiological surveillance on new species that could be introduced to AMBA with new clinical manifestations and severity.

References

Asociación Toxicológica Argentina. [on line]. Tres casos de picadura de alacrán alertan al país. [Accessed: January 17th, 2018]. Available at: <https://www.toxicologia.org.ar/tres-casos-picadura-alacran-alertan-al-pais/>

Blanco G., Laskowicz R., Scarlatto E., Casas N., Costa de Oliveira V., Lanari L., Lago N., de Roodt A. Increased incidence of *Tityus trivittatus*. Envenoming in the City of Buenos Aires. *Toxicon*. 2012;60(2):188.

Bortoluzzi L.R., Morini Querol M.V., Quero L.E. Notas sobre a ocorrência de *Tityus serrulatus* Lutz & Mello, 1922 (Scorpiones, Buthidae) no oeste do Rio Grande do Sul, Brasil. *Biota Neotrop*. 2007;7(3):357-359.

Boyer L.V., Theodorou A.A., Berg R.A., Joanne Mallie R.N., Chávez-Mendez A., García-Ubbelohde W., Hardiman S., Alagón A., for the Arizona Envenomation Investigators. Antivenom for critically ill children with neurotoxicity from scorpion stings. *N Engl J Med*. 2009;360(20):2090-2098.

Camargo F.J., Ricciardi A. Sobre la presencia de un escorpión *Tityus serrulatus* Lutz e Mello (Scorpiones, Buthidae) en la ciudad de Corrientes. *Comunicaciones Científicas y Tecnológicas* 2000, UNNE, Actas; Universidad Nacional del Nordeste, Argentina, 2000.

Chippaux J.P., Goyffon M. Epidemiology of scorpionism: a global appraisal. *Acta Trop*. 2008;107(2):71-79.

de Roodt A. Escorpionismo en Argentina [on line]. Asociación Toxicológica Argentina. [Accessed: January 17th, 2018]. Available at: <http://www.toxicologia.org.ar/opiniones/escorpionismo-en-argentina/>

de Roodt AR. Comments on Environmental and Sanitary Aspects of the Scorpionism by *Tityus trivittatus* in Buenos Aires City, Argentina. *Toxins* (Basel). 2014;6(4):1434-1452.

de Roodt AR, Lanari LC, Laskowicz RD, Costa de Oliverira V. Identificación de los escorpiones de importancia médica en la Argentina. *Acta Toxicol Argent*. 2014;22(1):5-14.

de Roodt A.R. Estudio del Veneno de Algunos Escorpiones de Importancia Médica de la Argentina. Master in Science thesis, Universidad Nacional de San Martín, San Martín, Buenos Aires, Argentina, 2009.

de Roodt A.R., Lago N.R., Salomón O.D., Laskowicz R.D., Neder de Román L.E., López R.A., Montero T.E., del V Vega V. A new venomous scorpion responsible for severe envenomation in Argentina: *Tityus confluens*. *Toxicon*. 2009;53(1):1-8.

de Roodt A.R., García S.I., Salomón O.D., Segre L., Dolab J.A., Funes R.F., de Titto E.H. Epidemiological and clinical aspects of scorpionism by *Tityus trivittatus* in Argentina. *Toxicon*. 2003;41(8):971-977.

Docampo P., Fernández M. Escorpionismo: presentación de un posible caso grave ocurrido en la Ciudad Autónoma de Buenos Aires. *Acta Toxicol Argent*. 2011,19(1):16-18.

El Ancasti. Desde hace 4 años nadie moría por picadura de alacrán. San Fernando del Valle de Catamarca, Argentina. [on line]. El Ancasti 2012 October 6th. [Accessed: January 17th, 2018]. Available at: <https://www.elancasti.com.ar/info-gral/2012/10/6/desde-hace-anos-nadie-moria-picadura-alacran-190188.html>.

El Ancasti. Adolescente en grave estado por la picadura de un alacrán. San Fernando del Valle de Catamarca, Argentina. [on line]. El Ancasti 2016 January 20th. [Accessed: January 17th, 2018]. Available at: <https://www.elancasti.com.ar/info-gral/2016/1/20/adolescente-grave-estado-picadura-alacran-285733.html>.

Isbister G.K., Bawaskar H.S. Scorpion Envenomation. *N Engl J Med*. 2014;371(5):457-463. Khatlaji A., Soulaymani-Bencheikh R., Achourb S., Salmie L., for the Scorpion Consensus Expert Group. Classification of clinical

consequences of scorpion stings: consensus Development. *Trans R Soc Trop Med Hyg.* 2011;105(7):364-369.

Martino O., Orduna T.A., Espinosa M. Atlas de patología humana provocada por la agresión de animales. Ideográfica, 2001.

Mayo Clinic. Disease and conditions: Scorpion Sting. [on line]. Mayo Clinic, Rochester, Minnesota, United States: Mayo Clinic Staff. [Updated on October 6th, 2016; Accessed: January 17th, 2018]. Available at: <https://www.mayoclinic.org/diseases-conditions/scorpion-stings/symptoms-causes/syc-20353859>.

Ministerio de Salud de la Nación. Guía de Prevención, Diagnóstico, Tratamiento y Vigilancia Epidemiológica del Envenenamiento por Escorpiones. Programa Nacional de Prevención y Control de las Intoxicaciones. Ministerio de Salud, Argentina. 2011. 40 p.

Ministerio de Salud de la Nación. Programa de Prevención y Control de Intoxicaciones. [on line]. Dirección Nacional de Determinantes de la Salud, Ministerio de Salud, Presidencia de la Nación. [Accessed: January 17th, 2018]. Available at: <http://www.msal.gov.ar/determinantes/index.php/datos/programa-nacio->

[nacional-de-prevencion-y-control-de-las-intoxicaciones](http://www.msal.gov.ar/determinantes/index.php/datos/programa-nacional-de-prevencion-y-control-de-las-intoxicaciones).

Ministerio de Salud de la Nación. Programa Nacional de Prevención de las Enfermedades Zoonóticas. Prevención ante la aparición de alacranes. [on line]. Ministerio de Salud, Presidencia de la Nación. [Accessed: January 17th, 2018]. Available at: <http://www.msal.gov.ar/zoonosis/index.php/informacion-para-adolescentes/animales-ponzonosos-venenosos>.

Ojanguren-Affilastro A.A., Adilardi R.S., Cajade R., Ramírez M.J., Ceccarelli F.S., Mola L.M. Multiple approaches to understanding the taxonomic status of an enigmatic new scorpion species of the genus *Tityus* (Buthidae) from the biogeographic island of Paraje Tres Cerros (Argentina). *PLoS One.* 2017,12(7):e0181337.

Piola J.C., Prada D.B., Waksman J.C., Evangelista M. Increase mortality and morbidity from *Tityus trivitattus* envenomation in Argentina. *Clin Toxicol.* 2006;44(5):650.

Salomón O.D., de Roodt A.R. Escorpiones: denuncia espontanea en dos centros de referencia en la ciudad de Buenos Aires, 1997-2000. *Medicina (Buenos Aires).* 2001;61(4):391-396.